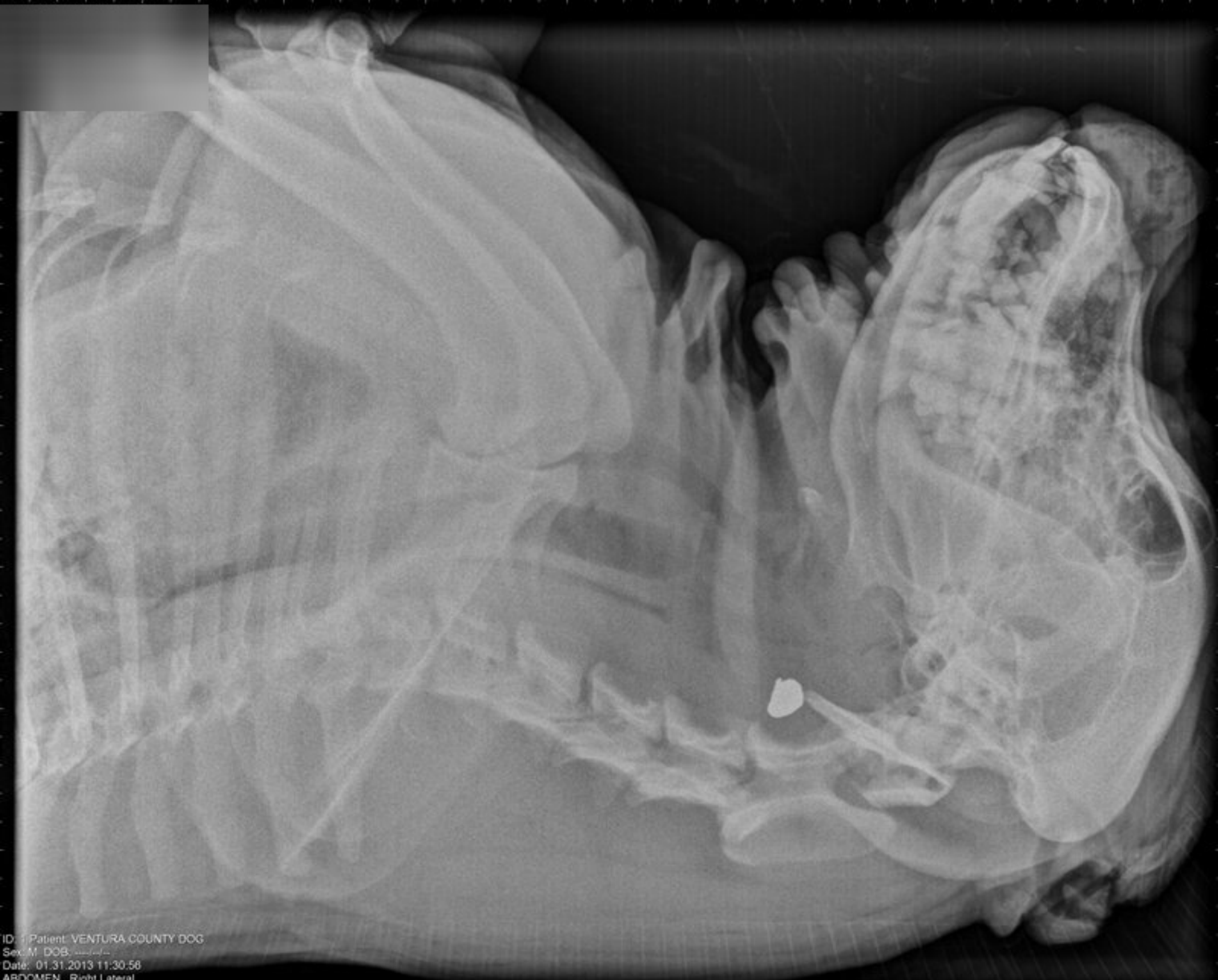
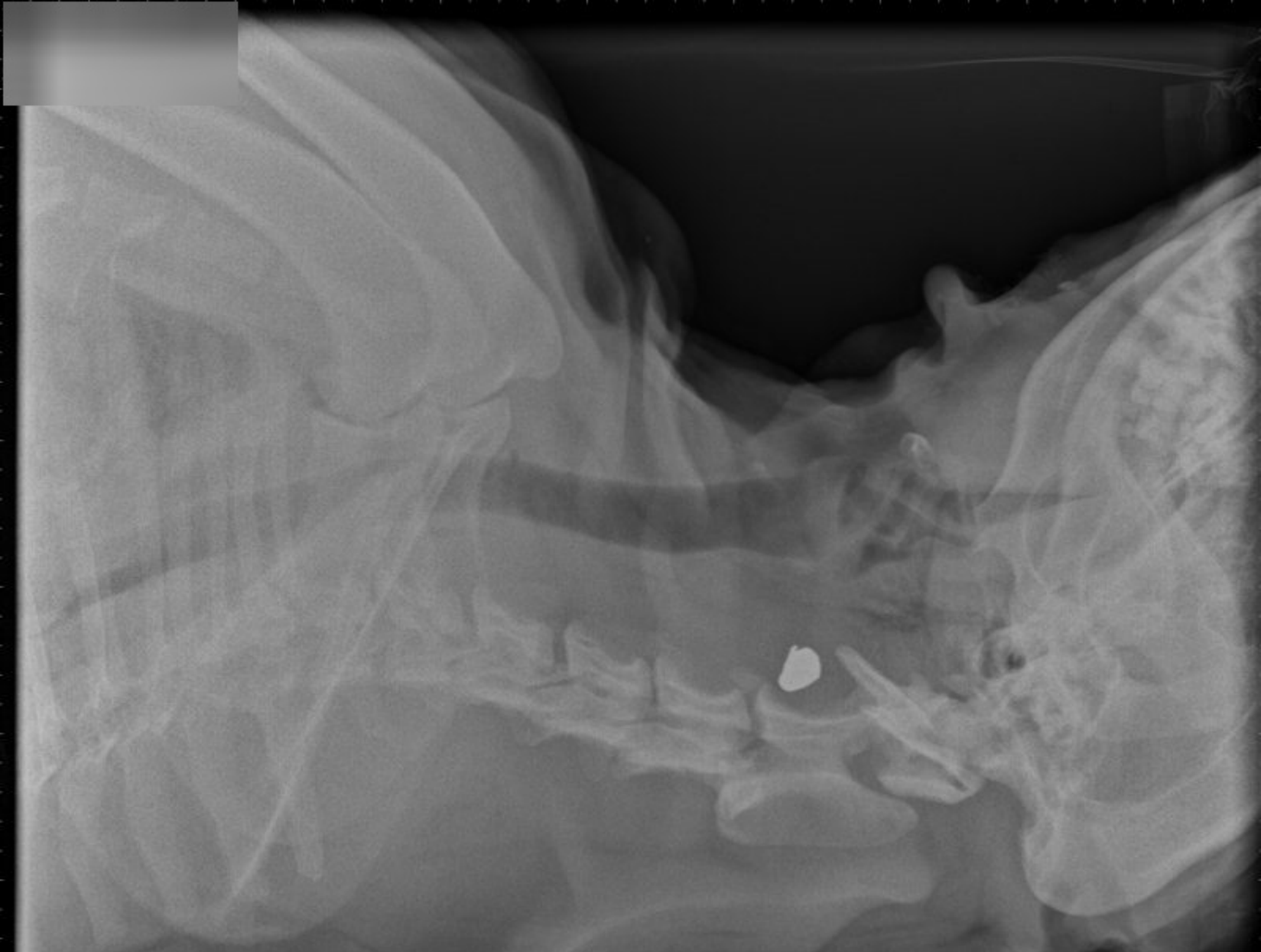


This is a right lateral X-ray of the abdomen. The image shows the skeletal structure, including the ribs, spine, and pelvis. The internal organs, such as the stomach and intestines, are visible as darker, more complex shapes. The spine is clearly visible, showing the vertebrae and intervertebral discs. The ribs are also clearly visible, curving around the chest and abdomen. The overall image is in grayscale, typical of medical X-rays.

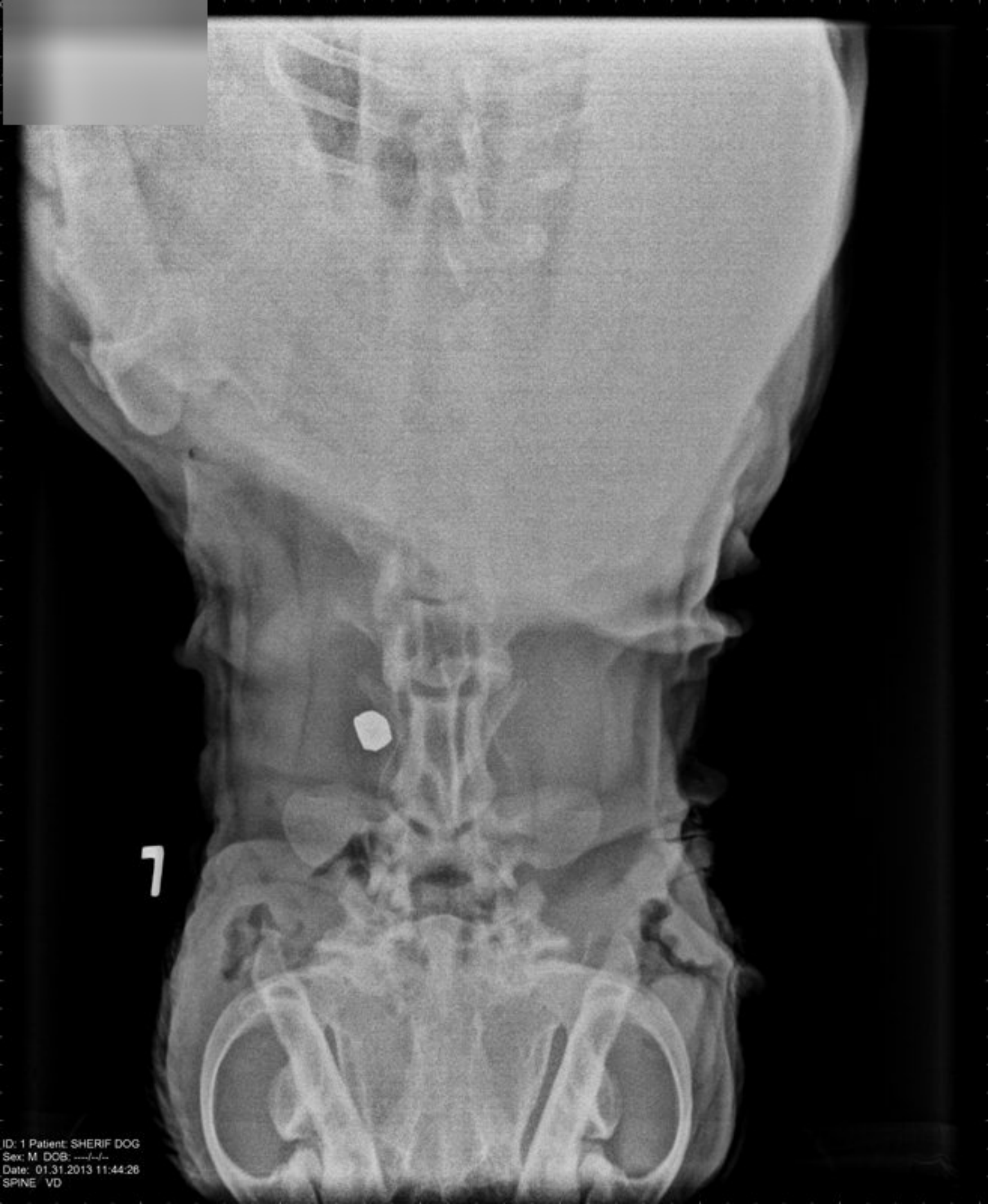ID: 1 Patient: SHERIF OOO
Sex: M DOB: ---/---/---
Date: 01.31.2013 11:33:15
ABDOMEN Right Lateral



ID: 1 Patient: VENTURA COUNTY DOG
Sex: M DOB: / /
Date: 01.31.2013 11:30:56
ABDOMEN Right Lateral



ID: 1 Patient: SHERIF DOG
Sex: M DOB: *unreadable*
Date: 01.31.2013 11:45:28
THORAX Right Lateral



ID: 1 Patient: SHERIF DOG
Sex: M DCB: ---/---
Date: 01.31.2013 11:44:26
SPINE VD